Definitions

- Anoxia: – Complete lack of oxygen.
- Hypoxia: – Decreased availability of oxygen
- Hypoxemia: – Decreased arterial concentration of oxygen.
- Ischemia: – Insufficient blood flow to cells or organ resulting in interrupted metabolism and death of the cell or organ affected

Scanned with CamScanner

Definition

- Perinatal asphyxia/neonatal asphyxia/birth asphyxia is the medical condition resulting from deprivation of oxygen to a newborn infant.

Scanned with CamScanner

AAP CRITERIA

- Umbilical artery blood pH < 7.0.
- 5 minute apgar score < 3,
- Neonatal Encephalopathy manifesting as
- seizures, hypotonia or coma in the immediate neonatal period.
- Evidence of multiorgan dysfunction.

Scanned with CamScanner

Why it is Important

- Perinatal Asphyxia is the leading cause of neonatal death (along with infection, prematurity and LBW).
- It is the leading cause of neurodevelopmental disability in children.
- The term perinatal asphyxia is preferred to Birth Asphyxia as asphyxia may occur before, during and after birth.

Scanned with CamScanner

Etiology

- Maternal factors:

  Hypoxia, anemia, diabetes, hypertension, smoking, nephritis, heart disease.

- Delivery conditions:

  Abruption of placenta, placenta previa, prolapsed cord, premature rupture of membranes,etc

- Fetal factors:

  Multiple birth, congenital malformations

Scanned with CamScanner

Abruptio placenta

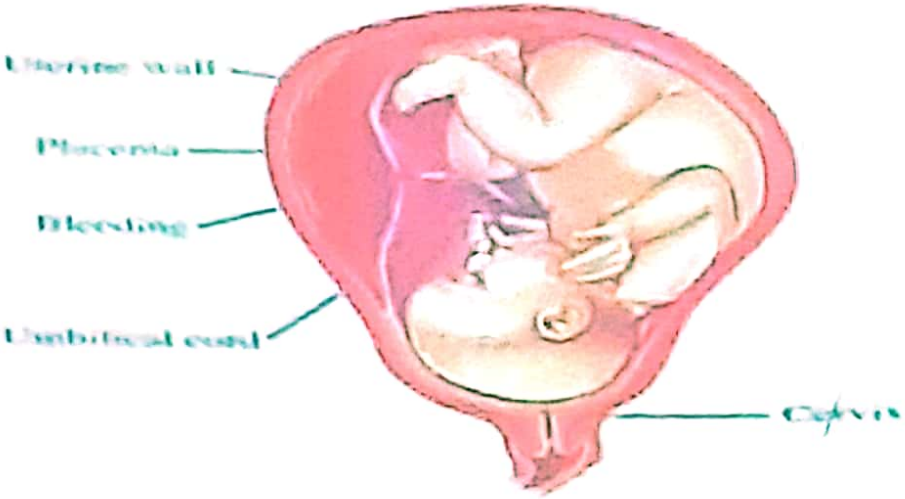

Scanned with CamScanner

Nuchal cord

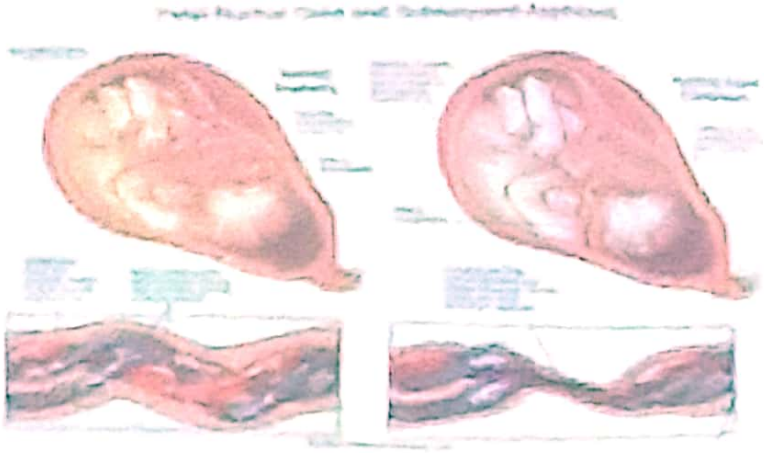

Scanned with CamScanner

Cord compression

Scanned with CamScanner

Pathophysiology

- When fetal asphyxia happens;
- self-defense mechanism which redistribute blood flow to different organs called "inter-organs shunt" in order to prevent some important organs including brain, heart and adrenal from hypoxic damage.

- Diving Seal Reflex :Shunting of blood to brain, heart and adrenals and away from lungs, gut, kidneys, liver, spleen and skin, in an attempt to maintain perfusion to more vital organs.

Scanned with CamScanner

Pathophysiology

- When fetal asphyxia happens;
- self-defense mechanism which redistribute blood flow to different organs called "inter-organs shunt" in order to prevent some important organs including brain, heart and adrenal from hypoxic damage.

- Diving Seal Reflex :Shunting of blood to brain, heart and adrenals and away from lungs, gut, kidneys, liver, spleen and skin, in an attempt to maintain perfusion to more vital organs.

Scanned with CamScanner

Pathophysiology

Hypoxic cellular damages:

a. Reversible damage(early stage):

Hypoxia may decrease the production of ATP, and result altered cellular functions . Reversible if hypoxia is reversed in short time.

b. Irreversible damage:

If hypoxia persists, the cellular damage will become irreversible that means even if hypoxia disappears but the cellular damages will not recover.

Scanned with CamScanner

Necrosis vs. Apoptosis

Two types of cell death:

- Necrosis (early cell death): Brief / severe insult, ATP-dependent Na+/K+ pumps fail, Na then H_20 influx, cell swelling, membrane fragmentation, inflammation.
- Neuron is destroyed. Post-event cooling not helpful.
- Apoptosis (delayed cell death): longer / milder insult, membrane depolarization, glutamate release, calcium influx, cell shrinks, no inflammation.
- Cascade of Apoptosis: Starts 2-6hrs after event.

  Window of opportunity for body cooling therapy.

Scanned with CamScanner

Clinical manifestations(Fetal Asphyxia)

- Fetal asphyxia
- Fetal heart rate: Tachycardia bradycardia
- Fetal movement: increase decrease
- Amniotic fluid: meconium-stained
- Biophysical profile

Scanned with CamScanner

Clinical manifestations

- Apgar score:
  - A: appearance(skin color)
  - P: pulse(heart rate)
  - G: grimace(reactive ability)
  - A: activity(muscle tone)
  - R: respiration

Scanned with CamScanner

Organ injury during asphyxia

Central nervous system: hypoxic ischemic encephalopathy, infarction, ICH, seizure, cerebral edema, hypertonia, hypotonia.

Cardiovascular system: myocardial ischemia, poor contractility, cardiac shock, transient ventricular hypertrophy.

Respiratory system: pulmonary hypertension, pulmonary hemorrhage, respiratory distress syndrome.

Gastrointestinal system: ulceration with hemorrhage, necrosis, perforation.

Adrenal: adrenal hemorrhage

Kidney: acute tubular or cortical necrosis

Skin: subcutaneous fat necrosis

Metabolic : SIADH, hyponatremia, hypo/hyperglycemia, hypocalcemia, myoglobinuria, hyperammonemia, hyperuricemia, hyperkalemia, elevated liver enzyme

Hematology : disseminated intravascular coagulation – transient left shift (neu)

Scanned with CamScanner

Diagnosis

- Evidence of fetal distress
- Fetal metabolic acidosis
- Abnormal neurological state
- Multiorgan involvement

Scanned with CamScanner

Classification

- Mild(stage I): hyperalert, irritable, normal muscular tone & reflex, no seizure, normal EEG
- Moderate(stage II): lethargy, hypotonia, weak sucking & Moro response, often seizure, EEG+
- Severe(stage III): coma, absent muscular tone & reflex, persistent seizure, EEG++

Scanned with CamScanner

IMAGING

- **Ultrasound**

has limited utility in evaluation of hypoxic injury in the term infant; it is the preferred modality in evaluation of the preterm infant.

- **CT scans**

are helpful in identification of focal hemorrhagic lesions, diffuse cortical injury, and damage to the basal ganglia; CT has limited ability to identify cortical injury within the 1st few days of life.

- **Diffusion-weighed MRI**

is the preferred imaging modality because of its/ increased sensitivity and specificity early in the process and its ability to outline the topography of the lesion.

Scanned with CamScanner

HIE – Management

Cardiovascular: Maintain normal BP
Fluids: Avoid hypoglycemia and hyperglycemia
Treat seizures: prevent additional damage
Ventilation: Keep carbon dioxide level normal (40-50)
Avoid Hyperoxia: 100% Oxygen toxic (goal 85-95% sat.)

In past, no effective treatment. Now →

Treatment: Therapeutic Hypothermia

Scanned with CamScanner

HIE – Therapeutic Hypothermia

Mechanisms:

- Reduces metabolic rate (7-8 % lower / 1° C)
- Reduces ion flux (calcium, sodium)
- Decreases excitatory transmitter release
- Reduces vascular permeability and edema
- Reduces apoptosis

Scanned with CamScanner

Head Cooling

Coolcap RCT 2005

- 234 infants, mod-sev HIE
- 72hrs of head cooling
  (rectal 34-35° C).

Scanned with CamScanner

Whole Body Cooling
Trial 2005

Whole body cooling 72
(rectal temperature 33.5 c)

Shankaran NEJM 2005

Scanned with CamScanner

Prognosis

- Early Treatment Better Prognosis.
- Bad Prognosis:
- Initial cord or initial blood pH < 6.7,
- Low Apgar Score (0-3),
- High Base Deficit,
- Decrebrate Posture,
- Lack of spontaneous activity.

Scanned with CamScanner

Long Term Disabilities

- Developmental Delay,
- Cerebral Palsy,
- Microcephaly,
- Seizures
- Blindness,
- Deafness,
- Problems with cognition, memory, fine motor skills.

Scanned with CamScanner

PROGNOSIS

- Moderate Encephalopathy:
  - Mortality– 10 to 30%
- Severe Encephalopathy:
  - Mortality: 60%
  - Disability: 100%

Scanned with CamScanner

Long Term Disabilities

- Developmental Delay,
- Cerebral Palsy,
- Microcephaly,
- Seizures
- Blindness,
- Deafness,
- Problems with cognition, memory, fine motor skills.

Scanned with CamScanner